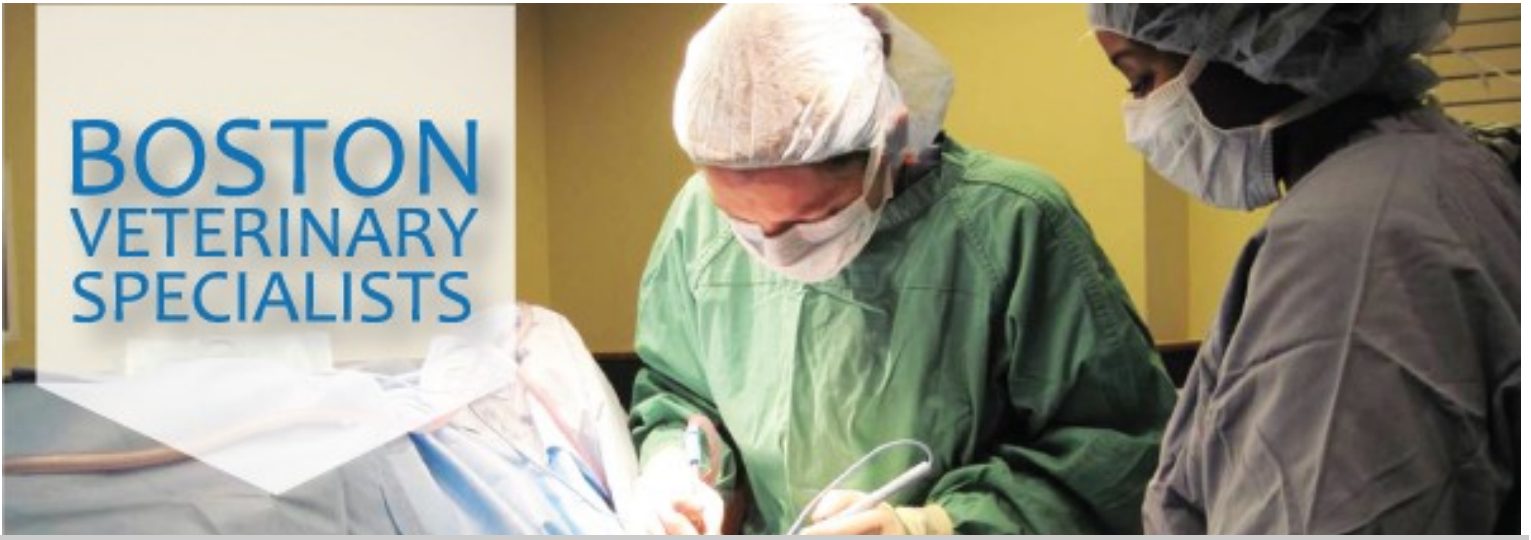



Monthly Update

Issue Contributors: Michelle Fulks, DVM, Virginia Sinnott, DVM, DACVECC, William B. Henry DVM, DACVS

Editor: William B. Henry DVM, DACVS

August 2013

Canine and Feline Coagulopathies

Michelle Fulks, DVM, Virginia Sinnott, DVM, DACVECC
William B. Henry, Jr. DVM, DACVS

Canine and Feline Coagulopathies

Bleeding disorders are considered a potential life-threatening emergency in small animal practice. It is crucial to recognize the potential for a coagulation disorder through history and physical exam findings, pursue appropriate diagnostic tests and then treat appropriately in order to prevent massive bleeding in these patients.

Three areas of the hemostatic system may be affected to cause coagulopathies:

1. Disorders of Primary Hemostasis
2. Disorders of Secondary Hemostasis
3. Disorders of Fibrinolysis

Primary hemostasis is the formation of the initial platelet plug. Decreases in platelet number, platelet function, or reduced von Willebrand factor (VWF) can all cause disorders of primary hemostasis and lead to mucosal bleeding or bruising. **Secondary hemostasis** is the formation of a stable fibrin clot via cascade of enzymes that ultimately convert fibrinogen to fibrin. Defects in coagulation factors can lead to severe bleeding diatheses. **Fibrinolysis** is the breakdown of the fibrin clot by plasmin. Excessive clot breakdown results in prolonged bleeding or delayed rebleeding.

Disorders of PRIMARY HEMOSTASIS

Thrombocytopenia is caused by decreased production, increased destruction or consumption and sequestration (Table 1). Platelet count must fall below approximately 50,000/mcL for spontaneous bleeding to occur.


Thrombocytopathias occur when platelet function is abnormal. The most common of these is von Willebrand disease, which may be inherited or acquired. VWD should be considered with unexplained bleeding in young dogs with or without trauma. It should also be considered when there is excessive bleeding following a planned trauma, such as a spay or neuter procedure. Although Dobermans and VWD is the most well recognized, certain other breeds may also be prone to inherited thrombocytopathias.

Disorders of Secondary Hemostasis

- Anticoagulant rodenticide toxicity inhibits vitamin K1 epoxide reductase resulting in dysfunction of factors II, VII, IX, X, protein C and protein S. Brodifacoum is the most common anticoagulant rodenticide used, and therefore ingested by our patients.
- Hepatic disease causes decreased or abnormal coagulation factor synthesis. This generally does not cause spontaneous bleeding.
- Cholestatic disease causes decreased absorption of vitamin K, which can cause dysfunctional forms of factors II, VII, IX and X.
- Inherited factor deficiencies. Factor VIII deficiency (ie, hemophilia) is most common, although other factor deficiencies may also occur.

Continued next page

Office News



Amanda Spencer, CVT joined our surgery team in late 2012. She has 10 years experience in surgery and emergency care. Her sole focus at BVS is with the surgical practice. Her skills, dedication to excellence, and caring attitude towards our clients and patients, has been outstanding. Her calm upbeat personality makes our days together as a team more enjoyable. She is one of those staff members "behind the public eye" who plays a vital role in our surgical practice.

Visit Our Newsletter Archive

Read our June newsletter article - **Tibial Tuberosity Advancement for CCL Injuries** - by visiting our newsletter archive!
<http://archive.constantcontact.com/fs032/1109892572426/archive/1110184841979.html>

Table 1: Causes of Thrombocytopenia

Decreased Production	
Primary	Neoplasia, immune-mediated, fibrosis, and myelophthisis
Drug-induced	Chloramphenicol, estrogen, bleomycin, lomustine, cytosine arabinoside, melphalan, methotrexate, platinum, doxorubicin, and actinomycin D
Secondary	FeLV, ehrlichiosis, and hypothyroidism
Consumption and Sequestration	Significant hemorrhage, splenomegaly, sepsis, vasculitis, and disseminated intravascular coagulation
Destruction	
Drug-induced	Furosemide, H2 receptor antagonists, cephalosporins, penicillins, trimethoprim-sulfamethoxazole, quinines, phenylbutazone, many cardiac medications
Primary	Inflammation and neoplasia
Secondary	Antibodies directed against normal platelet antigens
Infectious	Distemper, herpesvirus, parvovirus, adenovirus, FeLV, panleukopenia, FIV, FIP, ehrlichiosis, babesiosis, haemobartonellosis, rickettsiosis, leishmaniasis, cytauxzoonosis, borreliosis, dirofilariasis, histoplasmosis, candidiasis, leptospirosis, and septicemia.

Disorders of Fibrinolysis

Post-operative bleeding in greyhounds has been the most well described fibrinolytic disorder, but should be considered in other breeds with post-operative bleeding if VWD is not diagnosed.

Disseminated intravascular coagulation (DIC) is a disorder affecting all aspects of coagulation. The early stage is characterized by thrombosis, which results in excessive consumption of endogenous platelets and clotting factors. This consumption results in hemorrhage in the late stages. DIC is always secondary to an underlying issue such as severe trauma, neoplasia, sepsis, or overwhelming inflammation.

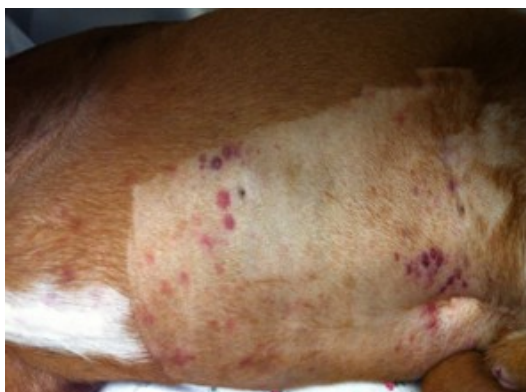History

A thorough history is essential and can help guide diagnostic tests. Signalment may help make inherited coagulopathies more likely. Breed predilection may also be seen, such as cocker spaniels, poodles and old English sheepdogs being over-represented in immune-mediated thrombocytopenia. Duration and progression of clinical signs as well as any recent trauma or surgery should be identified. The owner should also be questioned about any previous bleeding events such as with elective surgeries, teething or vaccination. Numerous repeated bleeding episodes in a young patient make inherited coagulopathies likely. Environment and travel history is also important, as certain infectious diseases are endemic in different regions. Medication history and any possibility of toxin exposure are other historical questions that should be addressed. Any patient with bleeding that may ultimately have a transfusion should be specifically asked about any previous transfusion history.

Physical exam

Physical exam findings may be related to sites of bleeding and can help increase suspicion for either primary or secondary hemostatic disorders. With primary hemostatic disorders capillary or small vessel hemorrhage is generally seen. Therefore, physical exam findings may include petechia (Figure 1), ecchymosis or mucosal hemorrhage such as epistaxis, hematuria, gingival bleeding, hematemesis, melena or hemoptysis. Secondary hemostatic disorders tend to have subcutaneous or cavity bleeding and physical exam findings are generally based on the location of the bleeding. Single or multiple hematomas may be seen with subcutaneous bleeding, dyspnea with pulmonary hemorrhage, dull lung or heart sounds with pleural hemorrhage, abdominal distension with hemoabdomens or lameness with hemorrhage into joints. Systemic signs of blood loss may also be identified and include lethargy, inappetance, collapse, pale mucous membranes, tachycardia and bounding or weak pulses.

Figure 1: Petechiation in a 4-year-old boxer with immune-mediated thrombocytopenia.



Diagnoses

Once a coagulopathy is suspected, results of laboratory coagulation testing are essential for disease classification. The following laboratory tests should be performed in patients with historical or physical exam findings suggestive of a coagulopathy:

- Complete blood count and blood smear evaluation should be performed to determine platelet count. It should also be evaluated for the presence of anemia or leukopenia, intracellular organisms and RBC morphology.
- Serum biochemical profile allows evaluation of total protein concentration and liver function studies.
- Buccal mucosal bleeding time (BMBT) should be performed in patients suspected of primary hemostatic abnormalities that have normal platelet counts. Prolonged BMBT indicates abnormal platelet function or vasculitis.
- Von Willebrand factor activity directly measures the amount of VWF and is used to diagnose and characterize type of VWD. Patients with prolonged BMBT with normal platelet counts should have VWF activity measured.
- Prothrombin time (PT) evaluates extrinsic (factor VII and tissue factor) and common (factors II, V, and X) coagulation pathways. Due to the half-life of factor VII, this is seen elevated first with anticoagulant rodenticide toxicities.
- Activated partial thromboplastin time (aPTT) evaluates intrinsic (factors VII, IX, XI, and XII) and common coagulation pathways. Prolonged aPTT with normal PT suggests specific factor abnormalities. PTT may also be mildly elevated with a normal PT with consumptive coagulopathies.

- Activated clotting time (ACT) also evaluates intrinsic and common pathways, but is less sensitive than aPTT.
- High-performance liquid chromatography (HPLC) is recommended if exposure to anticoagulant rodenticides is suspected but not confirmed, especially in cases where other differentials are likely (ie, hemangiosarcoma).
- Individual factor analysis should be performed to identify inherited factor deficiencies.
- Tests of fibrinolysis includes fibrinogen assays, thrombin time, fibrin degradation products and D-dimers.
 - Infectious disease screening should be performed to screen cases with primary hemostatic defects, fever, and/or generalized illness for Ehrlichia canis, Anaplasma phagocytophilum, Anaplasma platys, Rickettsia rickettsii by measuring antibody titers or PCR as indicated by geographic location.
- Bone marrow aspiration or biopsy is indicated with thrombocytopenia if other cell lines (RBC or WBC) are unusually increased or decreased.
- Radiographs and abdominal ultrasonography are indicated for pulmonary (Figure 2), pleural, or abdominal hemorrhage. They should also be performed to evaluate for primary disease processes in DIC (ie, masses and pneumonia).

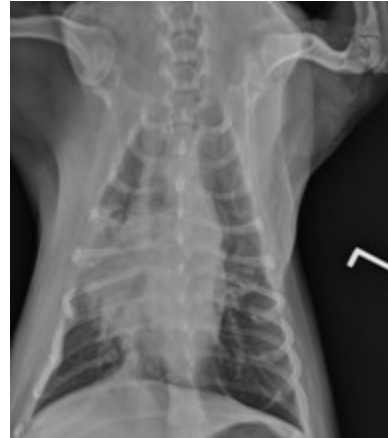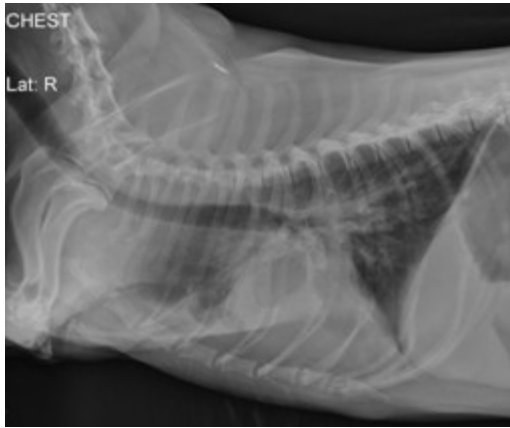


Figure 2: Lateral and ventrodorsal thoracic radiograph of a 9-year-old Welsh corgi following ingestion of an anticoagulant rodenticide unbeknownst to the owner at least 3 days prior to presentation. Note the mixed pattern of alveolar infiltrates and scant pleural effusion (hemorrhage).

- Advanced imaging such as CT scan or MRI are indicated in cases of central nervous system hemorrhage.

Table 2: Coagulation testing results used to identify type of hemostatic defect.

	Platelet count <50,000/mcL	PT	aPTT	Other
Thrombocytopenia	Yes	Normal	Normal	
Thrombocytopathia	No	Normal	Normal	Increased BMBT
Rodenticide	No, unless hemorrhage is extreme	Prolonged	Prolonged	
Hepatic Failure	No, unless hemorrhage is extreme	Prolonged	Prolonged	Abnormal liver values
DIC	Typically	Prolonged	Prolonged	Increased D-dimers
Hemophilia A+B	No, unless hemorrhage is extreme	Normal	Prolonged	Factor analysis

Treatment

The first goal in treatment in patients with life-threatening hemorrhage is to stabilize those in shock with IV fluid therapy. Isotonic crystalloids (lactated Ringer solution or 0.9% saline solution) should be used in increments of 20-30 ml/kg until heart rate, blood pressure, mucous membrane color and mental status are normal. Hypertonic saline (7.2-7.5% NaCl) may also be used for rapid intravascular volume replacement in patients that are not already dehydrated or hypernatremic. Hypertonic saline should be given at a dose of 4-6 ml/kg over no faster than 15 minutes followed by isotonic crystalloids. Packed red blood cells or fresh whole blood may also be indicated if the patient remains symptomatic after fluid resuscitation (ie tachycardia, abnormal pulses, hypotension, etc) or weak after IV fluid resuscitation. A packed cell volume of <20% after an episode of acute bleeding warrants consideration of a transfusion. A fresh whole blood transfusion would provide both red blood cells and clotting factors.

The second goal of treatment is to arrest bleeding, if possible. This includes transfusing missing clotting factors with fresh frozen plasma or cryoprecipitate. Fresh frozen plasma supplies clotting factors XII, XI, X, IX, VIII, VII, V, II, VWF and fibrinogen rapidly. FFP is indicated for hemophilia, VWD and anticoagulant rodenticide ingestion with hemorrhage. Frozen plasma may also be used to provide vitamin K dependent clotting factors for rodenticide toxicities and has a long shelf life. Cryoprecipitate is another treatment option for VWD. Desmopressin acetate stimulates release of VWF and is indicated in cases of VWD. It may be used pre-operatively prior to surgical procedures in patients known to have VWD to limit surgical hemorrhage. In thrombocytopenic patients, vincristine may be given to encourage platelet formation (as plasma provides very few platelets). Management of local bleeding should also be pursued if possible, by wrapping distensible areas such as an abdomen or subcutaneous space. Excising bleeding masses should also be pursued as soon as it is safe to do so.

The third goal of treatment for coagulopathies is to treat the underlying cause. These treatments will be diagnosis-specific and may include immunosuppressive medication, vitamin K1, or antibiotics. In patients with recent rodenticide ingestion (1 to 3 hours), immediate decontamination with apomorphine to induce vomiting and activated charcoal should be pursued. In these patients with successful decontamination, vitamin K therapy is not immediately indicated. A prothrombin time should be measured 48-72 hours after known exposure to anticoagulant rodenticides, and if results are within reference ranges administration of vitamin K therapy is not required. However, if PT is prolonged at this time or in patients that did not have immediate decontamination or are actively bleeding, oral vitamin K therapy (3-5 mg/kg divided q 12 hr for 4 weeks) should be initiated. The injectable form is poorly absorbed but necessary for cases when malabsorption of vitamin K is suspected such as cholestasis, liver failure (0.5-1 mg/kg SQ q12-24 hr) and shock. Doxycycline at 5-10mg/kg PO BID is indicated in cases of thrombocytopenia while infectious disease testing is pending.

Immunosuppressive medications (prednisone, azathioprine, cyclosporine, and leflunomide) are indicated to treat immune-mediated thrombocytopenia. Antifibrinolytic agents such as aminocaproic acid have been shown effective in greyhounds to prevent postsurgical bleeding.

Prognosis

Prognosis varies based on the type of coagulopathy and underlying cause. In cases of thrombocytopenia, those with infectious causes have a good long-term prognosis. However, the prognosis for immune-mediated thrombocytopenia is only fair and the risk of relapse is always present. Patients with hereditary coagulopathies (such as VWD or factor deficiencies) can live normal life spans, although multiple transfusions may be required throughout the course of their lives. Owners of these patients should be warned about clinical signs of bleeding and potential for multiple transfusions. They should be educated to inform any future veterinary providers about prior transfusions and history of coagulopathy. Patients with recent exposure to anticoagulant rodenticides that have immediate decontamination have an excellent prognosis. With un-witnessed ingestion and bleeding 3-5 days post-exposure, prognosis is still good but treatment is more costly due to the possible need of multiple transfusions. Patients with disseminated intravascular coagulation have a guarded prognosis, unless the underlying cause can be rapidly corrected.

References:

- 1. Bleeding disorders.** Hackner SG. In Silverstein DC, Hopper K (eds): Small Animal Critical Care Medicine, St. Louis: Elsevier, 2009, pp 507-514.
- 2. Inherited disorders of hemostasis in dogs and cats.** Barr JW, McMichael M. Topics in Companion An Med 27:53-58, 2012.
- 3. Inherited platelet disorders.** Boudreaux MK. J Vet Emerg Crit Care 22(1):30-41, 2012.
- 4. Inherited coagulopathies.** Carr, AP. In Ettinger SJ, Feldman EC (eds): Veterinary Internal Medicine, 6th ed-Philadelphia: Elsevier, 2005, pp 1929-1933.
- 5. Platelet disorders and von willebrand disease.** Brooks MB, Catalfamo JL. In Ettinger SJ, Feldman EC (eds): Veterinary Internal Medicine, 6th ed-Philadelphia: Elsevier, 2005, pp 1918-1929.
- 6. Rodenticides.** Murphy MJ. Vet Clin Small Anim 32:469-484, 2002.
- 7. Common rodenticide toxicoses in small animals.** DeClementi C, Sobczak BR. Vet Clin Small Anim 42:349-360, 2012.
- 8. Acquired coagulopathies.** DuFort RM, Matros L. In Ettinger SJ, Feldman EC (eds): Veterinary Internal Medicine, 6th ed-Philadelphia: Elsevier, 2005, pp 1933-1937.
- 9. Retrospective evaluation of the effectiveness of epsilon aminocaproic acid for the prevention of post amputation bleeding in retired racing Greyhounds with appendicular bone tumors: 46 cases (2003-2008).** Marin LM, Iazbik C, Zaldivar-Lopez S, et al. J Vet Emerg Crit Care 22(3):332-340, 2012
- 10. Diagnostic approach to small animal bleeding disorders.** Herring J, McMichael M. Topics in Companion An Med 27:73-80, 2012.
- 11. Assessment of platelet function.** Jandrey KE. J Vet Emerg Crit Care 22(1):81-98, 2012.
- 12. Blood transfusions and blood substitutes.** Hohenhaus AE. In Dibartola SP (ed): Fluid, Electrolyte, and Acid-base Disorders in Small Animal Practice, St. Louis: Elsevier, 2012, pp 585-604.
- 13. Rodenticides.** Brown AJ, Waddell LS. In Silverstein DC, Hopper K (eds): Small Animal Critical Care Medicine, St. Louis: Elsevier, 2009, pp 346-350.
- 14. Incidence of prolonged prothrombin time in dogs following gastrointestinal decontamination for acute anticoagulant rodenticide ingestion.** Pachtinger GE, Otto CM, Syring RS. J Vet Emerg Crit Care 18(3):285-291, 2008.
- 15. Therapeutic options for immune-mediated thrombocytopenia.** Nakamura RK, Tompkins E, Bianco D. J Vet Emerg Crit Care 22(1):59-72, 2012.
- 16. Approach to poisoning and drug overdose.** Schidt JC, Jutkowitz LA. In Silverstein DC, Hopper K (eds): Small Animal Critical Care Medicine, St. Louis: Elsevier, 2009, pp 326-329

Tech Tip

Editors Note: Canine Hip Dysplasia (CHD) is a common disease. As a Veterinary Technician or Veterinary Receptionist you should know this chronic painful disease can be avoided when diagnosed at a young age. The discussion below, although written to educate DVMs, should help you understand the need for early diagnosis. This in turn can be used to inform your clients with young puppies prone to the disease. (The bullet points are in bold type for a quick non medical read.)

Surgery STAT: Diagnosis and treatment of juvenile canine hip dysplasia

Oct/Nov 2009

By: William B. Henry Jr., DVM, Dipl. ACVS

DVM360 MAGAZINE

SurgerySTAT is a collaborative column between the American College of Veterinary Surgeons (ACVS) and DVM Newsmagazine. This month begins a two-part column by William B. Henry Jr., DVM, Dipl. ACVS. In Part 1 Dr. Henry writes about diagnosing canine hip dysplasia in young dogs. Part 2 in November will further discuss treatment of juvenile canine hip dysplasia, particularly the JPS procedure. Canine hip dysplasia (CHD) is a heritable polygenic condition compounded with environmental factors that results in laxity of the femoral head ligament. Laxity of the ligament allows hip subluxation. This laxity, along with incongruity of the coxofemoral joint, damages the acetabular labrum and femoral head cartilage, resulting in osteoarthritis (OA) and clinical pain.

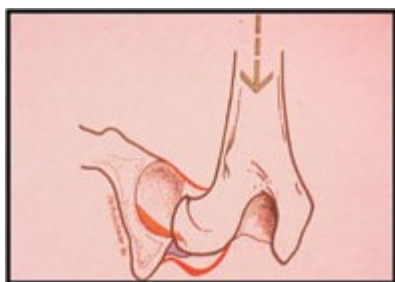


At 10 to 18 weeks of age, hip laxity seldom causes clinical signs unless it is severe in very large or overweight, active puppies. Diagnosis in the very young puppy can therefore be difficult.

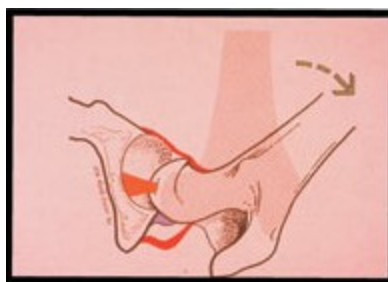
Because hip laxity is the No. 1 risk factor for developing OA in the hip joint, it is ideal for all puppies to be evaluated during routine examination. Two methods used to assist in the diagnosis of CHD in puppies are the Ortolani test and PennHip evaluation.

The Ortolani maneuver described in children can be easily learned and used in sedated puppies 10 to 18 weeks old to determine the presence of pathologic hip laxity (Photo 1: a-c). It is done with the puppy in lateral or dorsal recumbency. The femur is slowly abducted while applying a steady dorsal force to the femur and feeling for subluxation and reduction of the femoral head in the acetabulum. A positive Ortolani confirms hip laxity. A negative test does not rule out hip laxity; it may be a result of insufficient patient relaxation, osteoarthritis or severe abnormality of the coxofemoral anatomy (Photo 2).

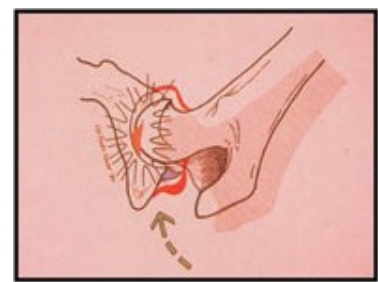
Photo 1: Palpation for Ortolani; The puppy is sedated and held in dorsal recumbency. Place your hand on the flexed knee and push the femur straight downward (dorsal) toward the acetabulum. A hip with pathologic laxity will subluxate out of the acetabulum (a). Continue to apply downward (dorsal) pressure on the femur and abduct it towards the table (b). At some point, usually between 20 and 45 degrees of abduction, the hip will relocate into the acetabulum. When this occurs there is a palpable drop as the femoral head seats in the acetabulum, often creating an audible sound (c). The palpable relocation of the femoral head back into the acetabulum is the Ortolani Sign, confirming pathologic laxity.



1a

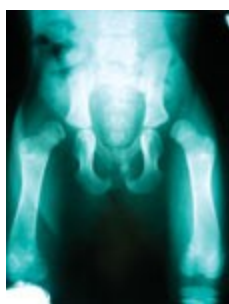

1b

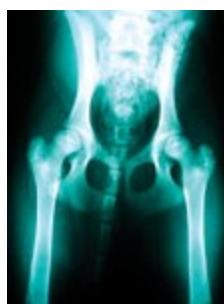

1c

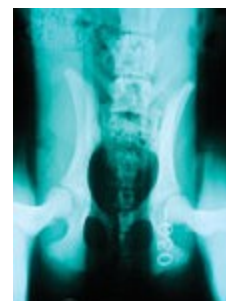Photo 2: VD pelvic radiograph of an 11-week-old Pit Bull cross showing severe dysplasia. This dog did not have an Ortolani because he has "no hip joint." This is shown to emphasize the importance of radiographs as well as palpation when evaluating for hip dysplasia.



2



3a



3b

Photo 3: VD and PennHIP distraction views of an 18-week-old Golden Retriever puppy. The hip extended VD view looks fairly normal (a); however, the PennHip distraction view confirms laxity (b).

PennHIP radiographs are a series of three radiographic views (hip extended, distraction and compression views) that allow for assessment of degenerative changes and an objective measurement of hip laxity, reported as the distraction index (Photo 3 a,b). An ideal PennHIP Distraction Index (DI) is 0.30 or less. 0.40 and above are indicative of laxity that would result in CHD and secondary arthritis, especially in the 0.50 to 1.0 (at 1.0 there is no functional hip joint as in Photo 2, above).

The technique uses the dog's neutral hip angle and a distraction device to yield the distraction index (DI). The DI is a number from 0 to 1 that quantifies the maximum amount the hip luxates out of the acetabulum under passive conditions. PennHIP distraction indices are highly predictive for the risk of development of osteoarthritis in puppies 4 months of age or older. The higher the DI, the greater chance of developing OA in life. This method cannot predict which dogs will have clinical signs of CHD, only the risk of developing OA. Puppies less than 18 weeks old that have a positive Ortolani and/or a **PennHIP distraction index consistent with hip dysplasia are potential candidates for juvenile pubic symphysiodesis surgery, which will be discussed in Part 2 of this column.**

PART 2:

Juvenile pubic symphysiodesis (JPS) surgery is a prophylactic procedure performed in puppies 10 to 18 weeks of age that have been diagnosed with hip dysplasia as discussed in last month's column. This technique was developed as our ability to diagnose hip dysplasia (coxofemoral joint laxity) in the immature dog improved, along with the recognition of pubic symphysis abnormalities in children born with hip dysplasia. JPS is a relatively simple procedure associated with little postoperative morbidity.

JPS surgery causes premature closure of the cranial pubic symphysis. The pubic symphysis is responsible for much of the longitudinal growth of the pubis. Premature closure of the cranial pubic symphysis results in shortened acetabular branches of the pubic bones. This, combined with normal growth elsewhere in the pelvis, results in outward rotation of the acetabuli, thereby improving coverage of the femoral heads. This is similar to the effect gained by triple pelvic osteotomy (TPO), but it occurs gradually during the rapid growth phase.

Closure of the cranial pubic symphysis is accomplished either with an electrocautery needle applied through the physeal cartilage following a specific protocol for time and wattage, or by removal of the physeal cartilage with No. 12 and No. 15 scalpel blades, small bone rongeurs and curettes, followed by cauterization of the bone edges. With either technique, the insertion of the prepubic tendon must be removed to allow placement of a protective instrument to avoid urethral damage.

Following surgery, the puppies are walked on a leash, avoiding running and jumping for eight to sixteen weeks. They are re-evaluated four to eight months after surgery by Ortolani palpation and standard ventrodorsal radiographs of the pelvis to assess acetabular coverage. The follow up evaluation time frame is based the DI score and the remaining growth of the puppy ie. a Springer Spaniel vs. a St. Bernard. Because hip dysplasia is a known heritable condition, neutering the pet is mandatory.

JPS is a minimally invasive, relatively inexpensive procedure associated with minimal morbidity and will eliminate or greatly minimize coxofemoral laxity and therefore the progression of OA. It is an day patient surgery, no overnight hospitalization is required.

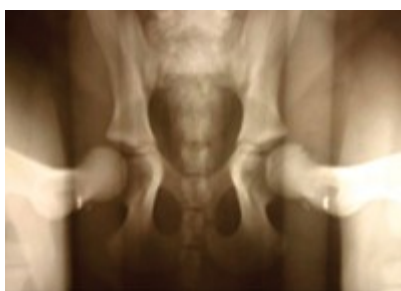

Photo 1: PennHip distraction view of a Labrador puppy at 14 weeks. The DI is 0.55.

JPS surgery is more successful at an early age when a significant potential for growth remains, especially in puppies with high distraction indices. A successful outcome is one in which good femoral head coverage is achieved and hip joint laxity resolves, precluding the necessity for more invasive surgical intervention in the future (such as TPO, femoral head ostectomy or total hip arthroplasty) (Photos 1-3).

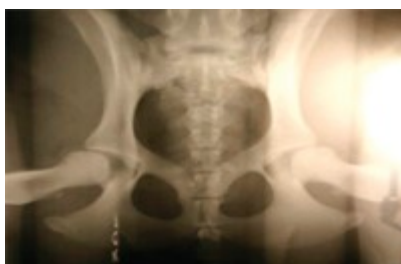

Photo 2: The same dog at 28 weeks (14 weeks post-JPS).

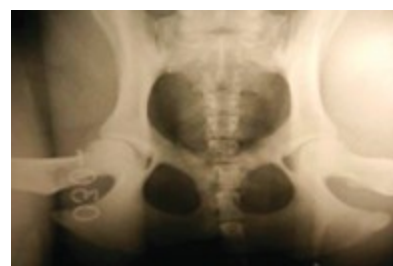

Photo 3: The same dog at 50 weeks (36 weeks post-JPS).

2

3

Hip dysplasia is a very prevalent, complex disease and, as such, veterinarians should strive to become competent in early detection of hip laxity and knowledgeable regarding the principles of the surgical options available. This will enable them to better counsel their technicians and clients regarding breeding strategies, exercise programs and dietary management, as well as potentially beneficial surgical options for affected puppies.

Dr. William B. Henry, Jr. is an ACVS board-certified veterinary surgeon and past president of the American College of Veterinary Surgeons (ACVS). He currently practices with Cape Cod Veterinary Specialists and Boston Veterinary Specialists. His primary interest is orthopedic surgery.

Visit <http://dvm360.com/surgery/> to access hundreds of articles on veterinary surgery.